



University of Calgary

PRISM: University of Calgary's Digital Repository

Research Centres, Institutes, Projects and Units

E-Health Resource Repository

2005-04-07

A Teledermatology Network for Underserved Areas of South Africa

Colven, R.; Todd, G.; Wynchank, S.; March, J.; Molefi, M.

Presented at Med-e-tel 2005 Conference in Luxembourg

<http://hdl.handle.net/123456789/3528>

Presentation

Downloaded from PRISM: <https://prism.ucalgary.ca>



A Teledermatology Network for Underserved Areas of South Africa

R. Colven¹, G. Todd², S. Wynchank³, J. March³, M. Molefi³

¹University of Washington School of Medicine, ²University of Cape Town Faculty of Health Sciences, and the ³Medical Research Council of South Africa



Puget Sound Partners for Global Health

Definitions

Telemedicine:

Practice of medicine across a distance.

Teledermatology:

One example of a telemedicine specialty.

Telemedicine:

Two Primary Modalities

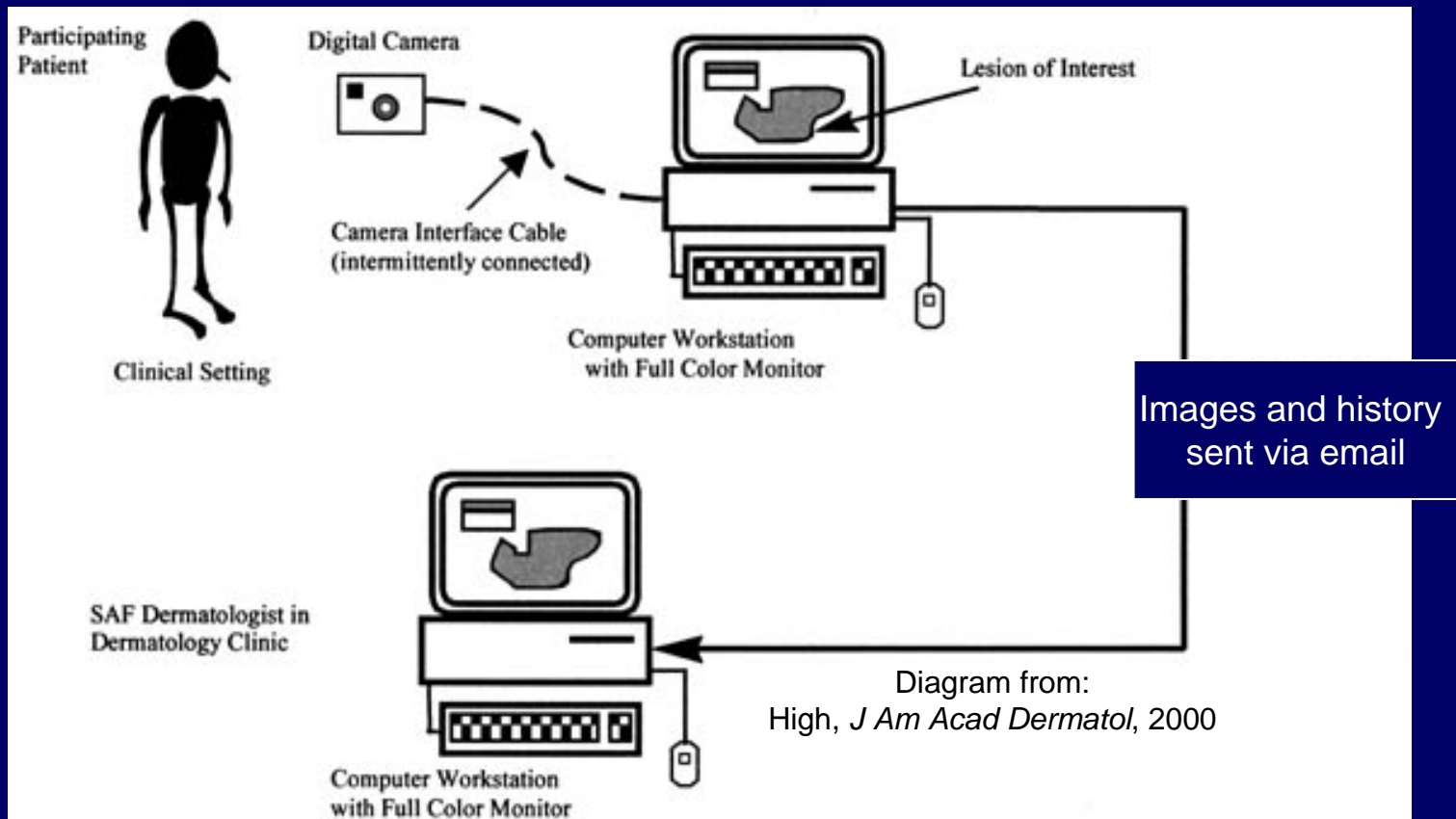
Live interactive video

- Synchronous (in real time)
- More closely simulates in-person visit
 - Converse with patient and referring provider
 - Patient can see you
- Lower resolution
- Equipment \$\$\$

Store-and-forward

- Not synchronous
- Patient doesn't interact with consultant
- Logistically straightforward
- Higher resolution
- Equipment \$

Store and Forward Telemedicine



A Teledermatology Network for Underserved Areas of South Africa

Fundamental Questions

- Is the telemedicine modality accurate?
- Is privacy protected?
- Will patients be satisfied with it?
- Will practitioners use it?
- Is it cost effective?

ICT Use South Africa

- Internet users (2002): 3.1 million (7%)
 - Ranks 36th in world
- Cell phones (2003): 17 million (39%)
 - 18th in world
- Land line phones (2002): 4.8 million (11%)
 - 33rd in world

Source: CIA World Fact Book online

The Burden of Skin Disease in South Africa

- 3-4 million patients/dermatologist
- HIV/AIDS: New twists to skin disease
- Resources limited
- Empirical treatment common (wasteful)
- Referral inconsistent

How can specialty care be delivered?

A Tele dermatology Network for S.A.

- Goal: Enhance delivery of dermatological care to underserved areas of S.A.
- Benefits:
 - Decrease morbidity/mortality from skin disease
 - Provide clinical education in skin disease recognition, management, and referral
 - Become a model of tele dermatology for regions of similar need

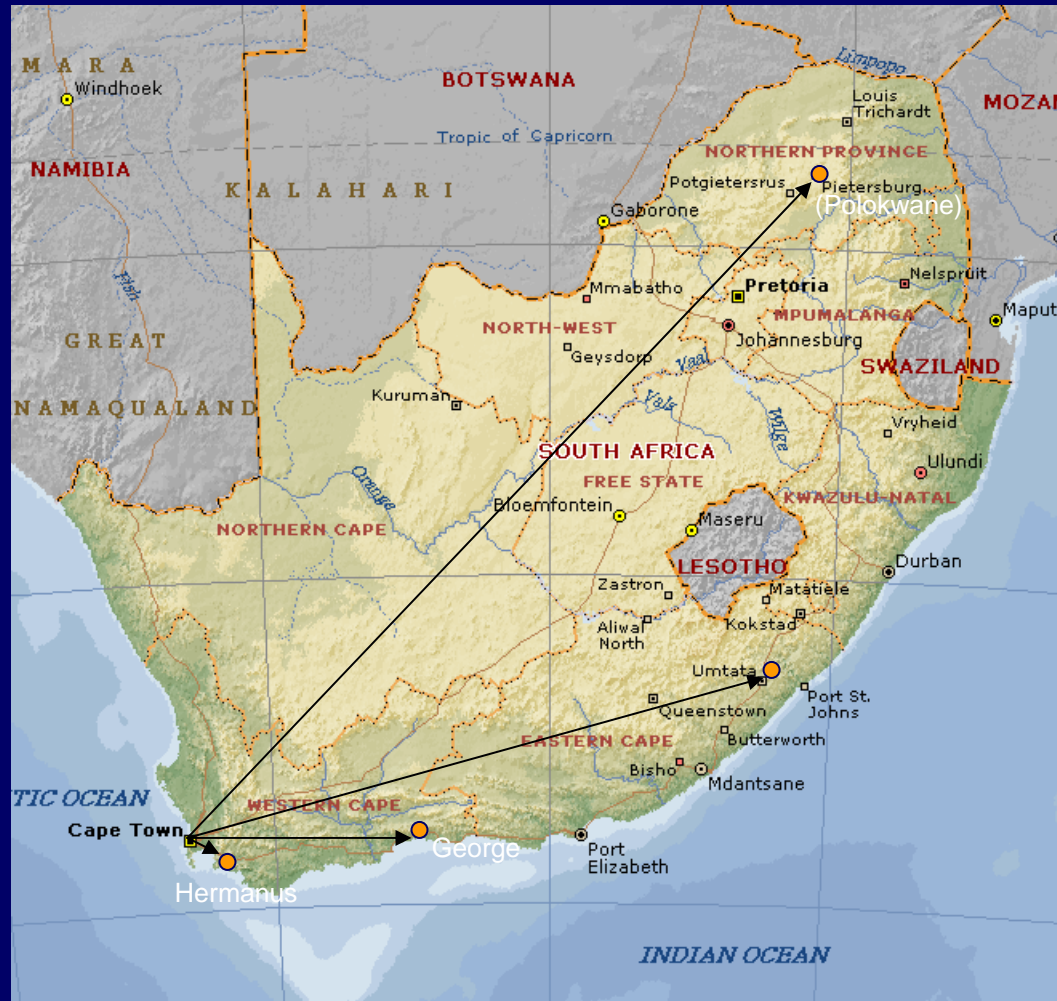Objectives

- Identify committed dermatologically underserved health care sites
 - Must be email-enabled
- Assure digital imaging equipment
 - Camera/computer
- Train providers in digital photography of skin lesions and image handling

Objectives (cont'd)

- Teledermatology consultations
 - Render opinion by email within 5-7 days
 - Sooner if required
 - Provide feedback to referring provider
 - Provide education/references
- Patient and provider surveys
 - Satisfied?
 - Helpful (improve outcome)?
- Periodic site visits to troubleshoot, review

Teledermatology Network for S.A.



Map reference: MS Encarta

Example Patient Referral

Via email:

Hi Roy

Please comment on this XX year old Xhosa man, painter for 10 years, completed TB treatment 1 year ago, who presents with these widespread itching ulcerating skin lesions for about 1 year.

I'm thinking of severe impetigo/secondary bacterial infection, upon some underlying condition such as scabies, eczema or secondary syphilis, or ?? SLE.

I tested him today for HIV and VDRL, awaiting results.

I've put him on Flucloxacillin, Phenergan, and aqueous cream, to see him next Friday.

I'll send you 3 e-mails, with 2 photos per e-mail, not to jam the server.

Would it be ok to make the pictures smaller in future - re loss of detail?

Regards

Example Response

A Teledermatology Network for Underserved Areas of South Africa
R. Colven—Principal Investigator—University of Washington & University of Cape Town

Dermatology Consultant Response

Date: 2 April, 2005
Date referral received: 1 April, 2005
Teledermatology Site: George
Patient code: 7 **Outpatient** **Provider code:** 1
Consultant Name: Roy Colven, MD **Institution:** UCT
Number of Images: 6
Total file size: 8.2 MB

Example Response

Case Summary:

XX year old male with one year history of itchy, eroded skin. History of TB, treatment completed 1 year ago. Works as a painter. No history of atopy mentioned. HIV status not yet known.

Teledermatological exam:

6 images show the extremities, buttocks, and face of an African adult male. The images show hyperpigmented plaques, papules and nodules, most eroded, and some, especially on the legs with heavy crusting. Most lesions appear chronic. His face shows a symmetrical pattern of hyperpigmented and erythematous plaques over the cheeks. He has some edema of his lower eyelids, but his conjunctivae look spared.

Example Response

Assessment:

This looks best for secondarily infected prurigo nodules. I will stick my neck out and predict that his HIV test will be positive. His arms, legs and buttocks have the appearance of “pruritic papular eruption” commonly seen in relatively advanced HIV. Staph carriage is likewise prevalent in HIV patients, making secondary infection a likely event. This is not to say that he couldn't have atopic eczema, or another systemic cause of itching with secondary lesions from scratching that have become infected. Secondary syphilis usually doesn't erode, and the one year history would make this unlikely. Easy to rule out, though.

Example Response

Recommendations:

I completely agree with your management thus far. In addition to the flucloxacillin and phenergan, I would also give him a topical steroid to help reduce the symptoms from these chronic lesions. Either Lenovate or 10% Dovate ointment would suffice, whichever you can give him in reasonable quantity. Ultimately, if he tests HIV seropositive, he would be a candidate for antiretrovirals.

Please let me know the results of his HIV test.

(Footnote: HIV+)

Example Response

Feedback for Referring Provider:

Image quality: Excellent

Historical data: Sufficient

Comments: none

Educational value: High

Review during next site visit? Yes

Example Response

References:

(assuming this patient ends up being HIV+)
Full PDF of this article is attached separately.

Etiology of pruritic papular eruption with HIV infection in Uganda.

Resneck JS Jr, Van Beek M, Furmanski L, Oyugi J, LeBoit PE, Katabira E, Kambugu F, Maurer T, Berger T, Pletcher MJ, Machtinger EL.

JAMA 2004; 292:2614-2621.

CONTEXT: A frequent cause of human immunodeficiency virus (HIV)-related morbidity in sub-Saharan Africa is a commonly occurring, intensely pruritic skin rash. The resulting scars are disfiguring and stigmatizing. Despite the substantial prevalence of pruritic papular eruption (PPE) among HIV-infected Africans, the cause has been elusive. (Abstract continues.)

Example Response

Please note:

This opinion, unless otherwise specified, is based solely on the historical data and images provided by the referring provider and does not reflect a complete review of the patient's history nor a complete physical, including skin, exam.

Immediate Benefits

- Specialist opinion
 - Triage, diagnostic support, management guidance.
- Dermatologist response rate 100%.
- *Timely.*
- Referral/response in medical record.
- Archive of images for future reference.
- Opportunity for referring provider learning.
- Further education with case review during site visits.

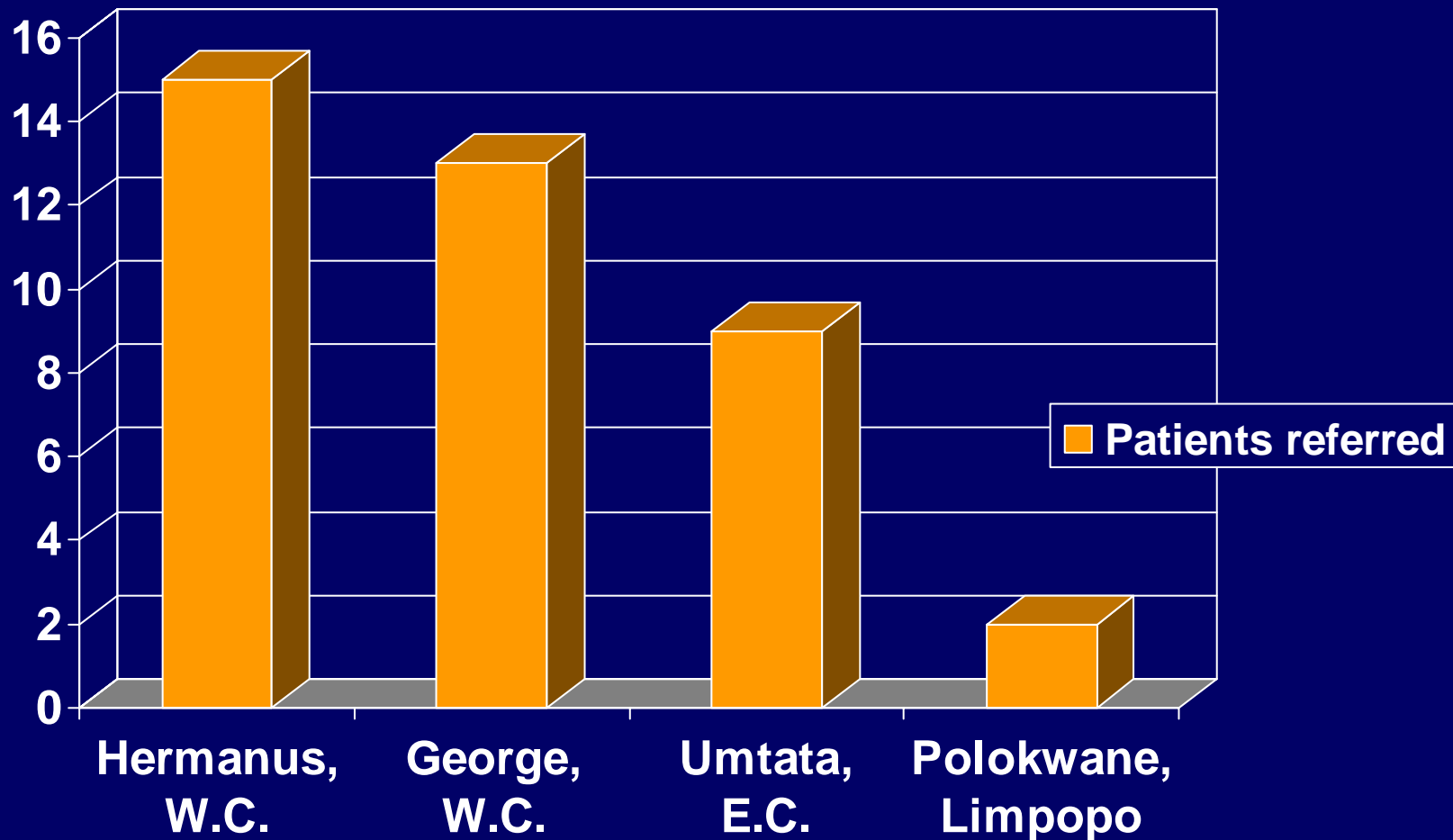
Pitfalls

- Historical information often insufficient.
 - Nurses better than doctors
- Image quality variable.
- Uploading images, history takes time.
- Consents/questionnaires add burden to referral.
- Equipment breaks down or goes missing.

Preliminary Results

- Patient Referrals: 40
- Providers: 8 (6 doctors, 2 nurses)
- Rashes 38 Solitary lesions 2
- Patient pigmentation
 - Darker 35
 - Lighter 4
 - Unable to tell 1
- Adults 32 Children 8
- Female 21 Male 18 Gender not given 1

Patient Referral by Site

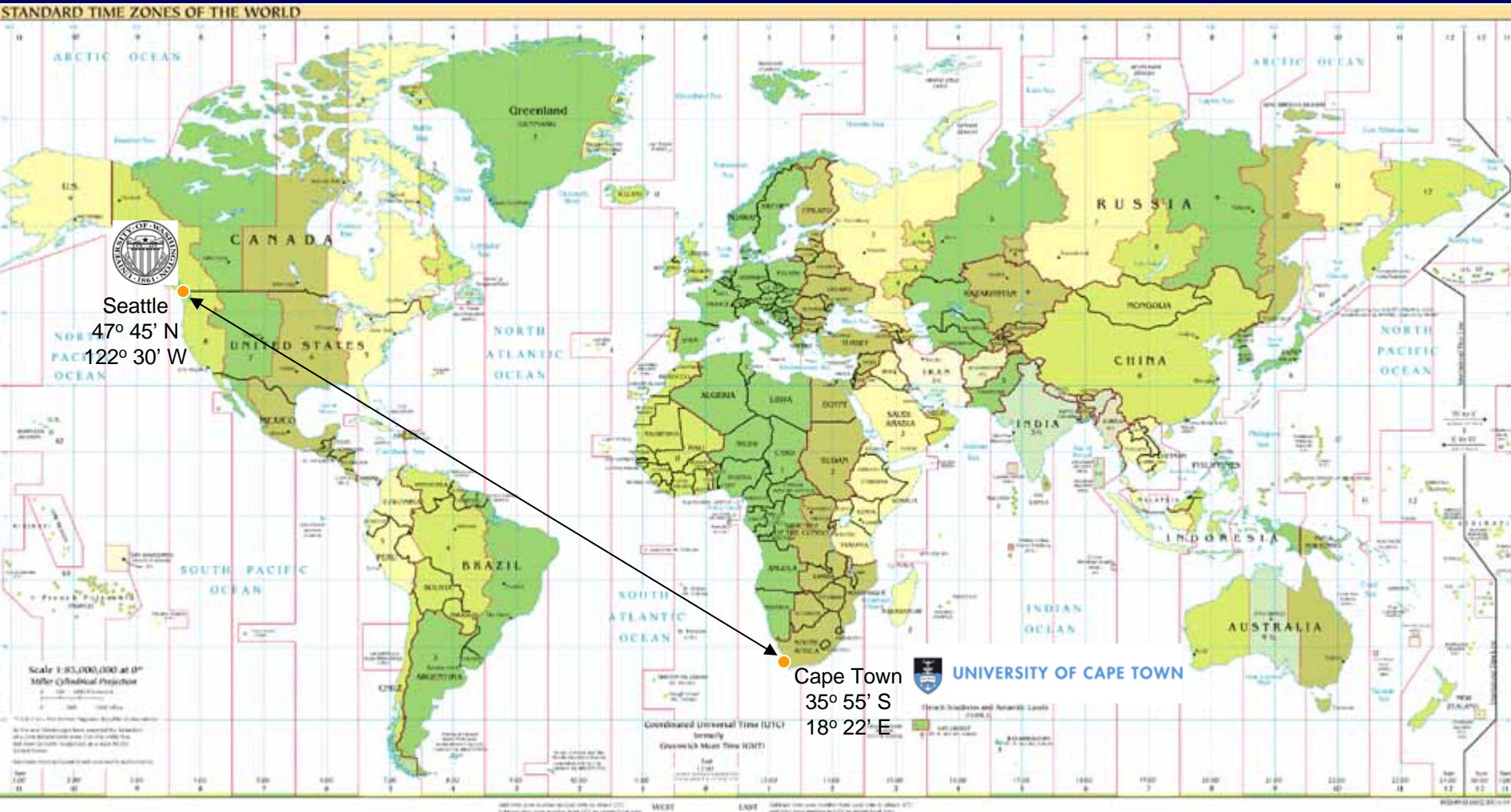


A Teledermatology Network for Underserved Areas of South Africa

Preliminary Results

- Insufficient history given: 17 (43%)
- Referrals where images not interpretable: 2 (5%)
- Patient comfort: Very good-excellent
- Patient satisfaction overall: Excellent
- Provider satisfaction overall: Excellent

University of Washington- University of Cape Town Dermatology Education Exchange



Future Directions

- Extend Network
 - SA Military
 - NGO's aiding with antiretroviral roll-out
 - Other sub-Saharan African nations
 - SA prison system
- Web-based, password-protected, referrals/responses
- Explore cellular network for transmitting images
- Establish system of reimbursement
- Extend network of teledermatologists
- Further research:
 - E.g., Assessment of diagnostic accuracy of rashes in darkly pigmented patients

Teledermatology South Africa Website

[http://faculty.washington.edu/rcolven/
teledermatology.shtml](http://faculty.washington.edu/rcolven/teledermatology.shtml)

Acknowledgements

- USA/South Africa Fulbright Commission
- Puget Sound Partners for Global Health
- Medical Research Council of South Africa
Telemedicine Research Centre
 - Moretlo Molefi, Sinclair Wynchank, Joleen March
- University of Cape Town/Groote Schuur Hospital
 - Prof. Gail Todd